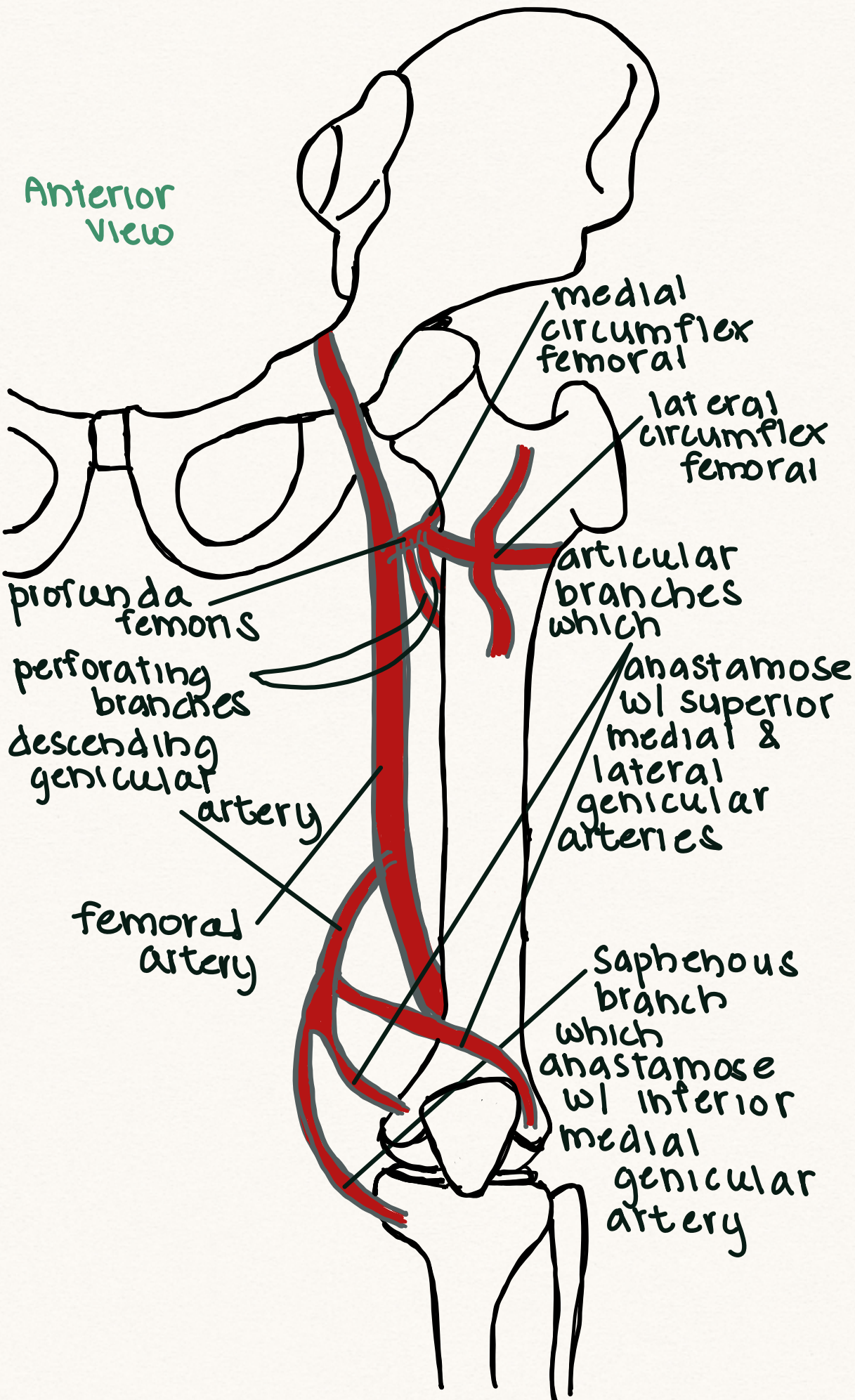


# HIP & KNEE ANASTAMOSESES

Anterior view



popliteal artery

posterior view

adductor hiatus

superior lateral genicular artery

superior medial genicular artery

middle genicular (dives into joint capsule)

inferior medial genicular artery

inferior lateral genicular artery

